



HAL
open science

Manual Reaction Times and Brain Dynamics after 'Awake Surgery' of Slow-Growing Tumours Invading the Parietal Area. A Case Report.

Etienne Sallard, Hugues Duffau, François Bonnetblanc

► **To cite this version:**

Etienne Sallard, Hugues Duffau, François Bonnetblanc. Manual Reaction Times and Brain Dynamics after 'Awake Surgery' of Slow-Growing Tumours Invading the Parietal Area. A Case Report.. *Brain Injury*, 2012, 26, pp.1750-1755. 10.3109/02699052.2012.698792 . lirmm-00805187

HAL Id: lirmm-00805187

<https://hal-lirmm.ccsd.cnrs.fr/lirmm-00805187>

Submitted on 27 Mar 2013

HAL is a multi-disciplinary open access archive for the deposit and dissemination of scientific research documents, whether they are published or not. The documents may come from teaching and research institutions in France or abroad, or from public or private research centers.

L'archive ouverte pluridisciplinaire **HAL**, est destinée au dépôt et à la diffusion de documents scientifiques de niveau recherche, publiés ou non, émanant des établissements d'enseignement et de recherche français ou étrangers, des laboratoires publics ou privés.

Manual reaction times and brain dynamics after ‘awake surgery’ of slow-growing tumors invading the parietal area. A case report.

Etienne Sallard^{1,2,3}, Jérôme Barral³, Hugues Duffau^{4,5}, François Bonnetblanc^{1,2,6*}

¹Unité de Formation et de Recherche en Sciences et Techniques des Activités Physiques et Sportives, Université de Bourgogne, F-21078 Dijon, Dijon, France.

²Institut National de la Santé et de la Recherche Médicale, Unité 1093, Cognition-Action et Plasticité Sensori-Motrice, France.

³Institut des Sciences du Sport de l’Université de Lausanne, Switzerland.

⁴Department of Neurosurgery, Hôpital Gui de Chauliac, Centre Hospitalier Universitaire Montpellier, France.

⁵Institut des Neurosciences de Montpellier INSERM U1051, France.

⁶Université Montpellier 2 – LIRMM – DEMAR Team, 161 Rue Ada, F-34095 Montpellier Cedex 5

*Corresponding author: francois.bonnetblanc@u-bourgogne.fr

Keywords: cerebral plasticity; slow-growing lesions.

Abstract

Primary objectives: Awake surgeries of slow growing tumors invading the brain and guided by direct electrical stimulation are accompanied by major brain reorganisations followed with slight impairments post-operatively. In most cases, these deficits are so slight after a few days that they are often not detectable on classical neuropsychological evaluations. Consequently, we investigated whether simple visuo-manual reaction times paradigms would sign some level of functional asymmetries between both hemispheres. Importantly, the visual stimulus was located in the saggital plan in order to limit attentional biases and to focus mainly on the interhemispheric asymmetry. Methods and procedures: Three patients (aged of 41, 59 and 59 years) after resections in parietal regions and a control group (age=44, SD 6.9) were compared during simple uni and bimanual reaction times (RTs).

Main outcomes and results: Longer RTs were observed for the contralesional compared to the ipsilesional hand in the unimanual condition. This asymmetry was reversed for the bimanual condition despite longer RTs. Conclusion and clinical implications: Reaction time paradigms are useful in these patients to monitor more precisely their functional deficits, especially their level of functional asymmetry and to understand brain (re)organisation following slow-growing lesions.

Keywords: awake surgery; simple reaction time; cerebral plasticity; parietal areas; slow-growing lesions.

Introduction

‘Low-grade gliomas’ (LGG, World Health Organization grade II gliomas) are slow-growing tumors invading the brain. During surgical resections of these tumors, the use of direct electrical stimulation (DES) is widely advocated for functional mapping, allowing the structures that are essential to the function to be identified and preserved at each stage of the resection [1]. Any reproducible functional disturbance induced by DES indicates interruption of the resection. This technique has proved to be effective and more than 90% of the patients return to normal socio-professional life, with no functional deficit, usually three months after the surgery [2].

However, in the context of slow-growing injuries, brain reorganisation is considerably increased than after acute lesions. The recruitment of remote brain areas in the ipsi- and contralesional hemispheres is much more efficient. Thus, the contrasting recoveries and plastic processes associated with the two types of lesion offer interesting insights that may help understanding brain plasticity [1, 3-5]. For slow-growing tumors, the impressive reorganisation capacity of the brain allows the subjects to recover substantially, deficits remain often undetectable with classical neuropsychological examinations and required extensive and more sensible evaluations [1, 3, 4, 6]. Despite clinical evidences, precise quantifications of these phenomena are lacking. More particularly, hand functional asymmetries measured using simple reaction times (RT) deserve to be investigated as they are illustrative of imbalance between both hemispheres for motor areas but also for associative and especially parietal areas involved in higher stages of motor planning and preparation [7]. When deficits cannot be precisely assessed using standard neuropsychological tests, simple reaction time paradigms could be interesting to probe the slight deficits characterizing patients with LGG. Indeed, this procedure may be used to track and monitor the level of functional

asymmetry between the two hemispheres occurring after the large resection performed within a single hemisphere.

In the context of slow-growing lesions, we investigated the inter-hemispheric imbalance after resections of LGG invading the parietal area for unimanual as well as for bimanual RT. Serrien and collaborators demonstrated that unilateral damage to the parietal lobe also impaired the synchronization of continuous bimanual movements [8]. In addition, it is known that actions driven and triggered by external stimuli (externally-driven) involve the parietal–premotor network which is less the case for self-paced-actions (internally-driven) that mainly involve the basal ganglia–supplementary motor network [9]. We thus contrasted the effect of externally versus internally generated movements during simultaneous bimanual movements. In this case report, we hypothesized that if simple visuo-manual reaction times would sign some level of functional asymmetries after an unilateral parietal resection, RT would be longer for the contralesional compared to the ipsilesional hand in the unimanual condition. Importantly, the visual stimulus was located in the saggital plan in order to limit attentional biases and to focus mainly on the interhemispheric asymmetry. Finally, resection in the parietal areas are expected to increase the onset asynchrony between the two hands during bimanual reaction time in the externally-driven condition compared to the internally-triggered condition.

Methods

Participants

Three patients (P1, P2 and P3) and 8 healthy volunteers (Control Group, age=44, SD=6.9) participated to the experiment (all right handed). The control group (5 males and 3 females) had no history of previous neurological diseases. The study conformed to the Code of Ethics of the World Medical Association (Declaration of Helsinki, 18 July, 1964) and the local ethics committees approved the general procedure.

P1, a 41 years-old man, presented a left parietal tumor (figure 1, upper and left panel). P2 and P3, two 59 years-old women presented a right parietal tumor (figure 1, upper middle and right panel). All these patients underwent surgical resection of low-grade glioma using intraoperative direct electrical stimulation.

P1 attended clinical observation because of epileptic seizures. He showed no deficit, especially no visuo-motor abnormality, on preoperative neurological examination before the surgery. In P1, the glioma was centered on the left parietal area as illustrated on the post-operative MRI. P2 was followed for a slow-growing right parietal tumor during 14 years, revealed by inaugural seizures. The neurological examination showed no visuo-spatial deficit. P3 experienced three somatosensory partial seizures 3 months before the surgery. The neurological examination was normal. Volumes of the tumor were estimated to approximately 50 cm³, 40cm³ and 37 cm³ for P1, P2 and P3 respectively.

Insert figure 1 about here

Task and procedure

Participants comfortably sat in front of two superimposed light emitting diode (LED) of different colors (red and green) fixed on a table at a distance of 60 cm from the body in the sagittal axis and 45 cm below the eyes. Importantly, the visual stimulus was located in the sagittal plan in order to limit attentional biases. Two switches were positioned on each side of the participant (distant = 15 cm from each other) and located at 45 cm from the body. Motor responses consisted in releasing one or two switch(es) by raising their index finger(s). The red LED served as the warning signal. The green LED represented the 'go-signal' prompting the participant to raise one or both index finger(s) as fast as possible. The time elapsed between the warning signal and the 'go-signal', i.e. the stimulus onset asynchrony (SOA), was randomly varied between each trial (SOA = 2, 2.5, 3, 3.5, 4 and 4.5 seconds).

Each participant performed the simple reaction time paradigm in four pseudo-randomized experimental conditions (three in the externally and one in internally condition). In the *right externally* (RE) or *left externally* (LE) conditions, they were asked to respond unilaterally with their right or left index fingers. In the *right and left externally* condition (RLE), they were required to raise both index fingers simultaneously. In the fourth *right and left internally* condition (RLI), they were asked to make a bimanual simultaneous response without external stimulus and raised their indexes in self-paced manner. Between 18 and 44 trials were performed for each condition according to the participant's motivation/tiredness. The measures of RT were performed at +96h, +72h and +48h after the operation for P1, P2 and P3 respectively. RTs were recorded at a sampling frequency of 5kHz and processed with a multichannel analog-to-digital converter (Biopac Systems, Inc., Goleta, California). RT values that exceeded twice the standard deviation from the RT mean were excluded from the analysis (5.39% of all trials).

Data analysis

RTs for the left and right fingers were compared using t-tests in the two unimanual conditions (RE and LE) as well as in the RLE bimanual condition (paired comparisons for this latter condition). T-tests were also used to compare pooled right and left RTs between the unimanual and the bimanual RLE condition. We measured the synchronization between the two hands (delta score) by subtracting the left hand to the right hand at each trial in the two bimanual conditions (Externally and Internally-driven). The negative values indicate that the left hand started before the right hand and conversely for the positive values. Within each bimanual condition, the delta scores were compared to zero to evaluate the synchrony of the responses of the two hands. T-tests were computed to compare delta scores between the RLI and RLE conditions. Mean RTs and mean delta scores were used for the statistical analyses in the control group. The significance threshold was fixed at 0.05.

Results

Results for the control group did not reveal any differences between the RE and LE unimanual RTs ($t(7)=-0.99$, $p=0.35$). However, RTs increased for all patients ($P_s<0.05$). For P1 and P2, analyses revealed a significant asymmetry between hands with shorter RTs for the ipsilesional (or non-lesed) hand compared to the contralesional (or lesed) hand (P1: $t(67)=2.45$, $p<0.05$ and P2: $t(59)=-2.12$, $p<0.05$). No significant differences was found for P3 ($t(64)=-0.84$, $p=0.4$). Note that it is the patient with the smallest resection. Mean RTs for the RE and LE unimanual conditions are shown in figure 2.

Results suggested that the two hands were perfectly synchronized for the control group in the bimanual externally condition as no significant difference was observed (RLE: $t(7)=-0.01$, $p=0.98$). Again, RTs increased for all patients ($P_s<0.05$). For the three patients, RTs were longer for the ipsilesional hand in comparison to the contralesional one ($t(33)=-5.73$, $p<0.01$ for P1; $t(32)=7.12$, $p<0.01$ for P2 and $t(22)=9.88$, $p<0.01$ for P3), showing that asymmetries of hands RTs performances were inverted between the unimanual (RE and LE) and the bimanual (RLE) conditions (figure 2). In addition, results revealed a general impairment of RTs in the bimanual condition as compared to the unimanual one for the two hands for P1 ($t(135)=-3.26$, $p<0.01$) and P3 ($t(110)=-5.19$, $p<0.01$). No such differences were found for P2 ($t(125)=0.64$, $p=0.51$).

 Insert figure 2 about here

In the bimanual internally condition (RLI), delta scores revealed a tendency to shorter RTs on the right hand for the control group ($t(7)=2.18$, $p=0.06$) and by contrast, shorter RT on the left

hand for all patients ($t(29)=-3.4$, $p<0.01$ for P1; $t(26)=-4.64$, $p<0.01$ for P2 and $t(34)=-5.75$, $p<0.01$ for P3) (figure 3).

Finally, asynchrony between both hands was more pronounced in the RLE condition in comparison to the RLI condition for all patients ($t(62)=5.78$, $p<0.01$ for P1; $t(58)=-2.63$, $p<0.05$ for P2 and $t(56)=-4.24$, $p<0.01$ for P3).

Insert figure 3 about here

Discussion

The aim of this experiment was to investigate simple hand reaction times asymmetries between the two hands following an ‘awake surgery’ of a LGG invading the parietal area.

This question was investigated both for unimanual and bimanual movements.

For unimanual movements, patients exhibited a general increase of hand RTs and longer RTs in favor of the contralesional hand in comparison to the control group. This functional asymmetry may sign changes in brain dynamics following ‘awake surgery’ of slow-growing tumors invading the parietal area and is in accordance with the hypothesis of an inter-hemispheric competition in which contralesional structures are disinhibited because of the lesions in the damaged hemisphere [10]. Similar findings, using repetitive transcranial magnetic stimulation applied over the parietal area in normal subjects, revealed that the detection of ipsilateral visual stimuli was improved over a normal level (i.e. RT decreased) whereas the detection of contralateral visual stimuli decreased (i.e. RT increased) [11, 12]. In accordance with our results, virtual lesions induced over the parietal area also provoked functional asymmetries in a reaction times paradigm.

For P1 and P3 we observed increased RTs during the bimanual condition in comparison to the unimanual one. This slowing down of motor responses during bimanual movements was previously reported for normal subjects [13-17] and is known as *bilateral deficit*. Two possible mechanisms have been suggested to explain this result: division of attention and interhemispheric inhibition [18, 19]. The division of attention assumes that when a bilateral movement is performed, a limited amount of attention is distributed to each hand. In the interhemispheric inhibition hypothesis, it is proposed that RTs increase during some bilateral movements as a result of callosal inhibitory mechanisms [20]. The *bilateral deficit* may be explained by the result of the crossing effect of mutual interhemispheric inhibition [21]. In any case, our results suggest that the *bilateral deficit* is greater after the removal of the

parietal area and that initiating the two hands simultaneously is more challenged for the patients. It has been suggested that for slow-growing lesions, the contralesional hemisphere may compensate for the damaged area [6, 8]. In consequence, we may speculate, that the contralesional homologue undergoes a kind of ‘bottleneck’ effect when the two hands are solicited simultaneously, that delays the motor response or challenges even more the bimanual coordination.

In contrast to unimanual movements, asymmetries of hands’ reaction times were inverted for bimanual ones in favor of the contralesional hand whatever the lesioned hemisphere. Despite no clear explanation of the mechanisms underlying this result, it stresses a strong different dynamics within the brain for uni- vs. bimanual movements. Finally, we observed that when performing bimanual movements in both the RLE and RLI conditions the onset asynchrony between the two hands increased for all patients. These asynchronies were more important in the RLE condition suggesting that they can not be explained solely by pure motor impairments but rather suggest some other attentional deficits involved in this latter condition. Finally, this case study confirm the involvement of the parietal area in externally-driven motor responses [9].

Limitation of the study

We are mindful that assessments of three patients with right or left parietal lesions and performing a different number of trials are limitations. But, it allowed an interesting viewing and comparison between lesions side in the parietal area after an ‘awake surgery’.

One might regret the lack of evaluation of attention deficits. Complementary results about line bisections ($l=25\text{cm}$) revealed small deviations toward the ipsilesional hemifield for P1 (-7.85mm) and P2 (0.95mm) and toward the contralesional hemifield for P3 (-1.4mm) that slightly contrasted with control performances (95% CI=[-0.45; 1.27]).

In consequence, despite a target presented at midline and the deviations were very small for P2 and P3, we cannot fully exclude some spatial attention deficits that might be confirmed by other neuropsychological tests.

Conclusions and clinical implications

In this case report including three patients, we observed consistent patterns of functional asymmetries with respect to the side of the lesion 1) in unimanual condition, RTs were steadily longer for the contralesional hand, 2) in bimanual condition, the RTs were constantly longer for the ipsilesional hand. These patterns of results do not allow a clear-cut interpretation. When deficits cannot be precisely assessed using standard neuropsychological tests, simple reaction time paradigms seem to be relevant to probe the slight deficits characterizing patients with LGG. Specifically, this method might help to monitor the level of functional asymmetry between the two hemispheres and be useful to guide the rehabilitation procedure. For patients with LGG, further researches should apply transcranial magnetic stimulation over the healthy homologue to determine its level of participation during recovery processes accompanying slow-growing lesions [6]. The chronometric method combined with transcranial magnetic stimulation could be a meaningful approach to increase knowledge about intra and inter-hemispheric cerebral dynamics in patients with slow-growing lesions.

Acknowledgment: This study was supported by the ‘Association pour la Recherche sur le Cancer’ (ARC-France Subvention Libre n°3184). We strongly thank the patients for their participation to this study.

Declaration of interest: The authors report no declaration of interest

References

- 1 H. Duffau. Lessons from brain mapping in surgery for low-grade glioma: insights into associations between tumour and brain plasticity. *Lancet Neurol* 2005;476-486-4.
- 2 H. Duffau, L. Capelle, D. Denvil, N. Sichez, P. Gatignol, M. Lopes, M. C. Mitchell, J. P. Sichez, R. Van Effenterre. Functional recovery after surgical resection of low grade gliomas in eloquent brain: hypothesis of brain compensation. *J Neurol Neurosurg Psychiatry* 2003;901-907-74.
- 3 F. Bonnetblanc, M. Desmurget, H. Duffau. [Low grade gliomas and cerebral plasticity: fundamental and clinical implications]. *Med Sci (Paris)* 2006;389-394-22.
- 4 M. Desmurget, F. Bonnetblanc, H. Duffau. Contrasting acute and slow-growing lesions: a new door to brain plasticity. *Brain* 2007;898-914-130.
- 5 D. G. Stein, S. Finger, T. Hart. Brain damage and recovery: problems and perspectives. *Behav Neural Biol* 1983;185-222-37.
- 6 E. Sallard, H. Duffau, F. Bonnetblanc. Ultra-fast recovery from right neglect after 'awake surgery' for slow-growing tumor invading the left parietal area. *Neurocase* 2012;80-90-18.
- 7 H. Foltys, R. Sparing, B. Boroojerdi, T. Krings, I. G. Meister, F. M. Mottaghy, R. Topper. Motor control in simple bimanual movements: a transcranial magnetic stimulation and reaction time study. *Clinical neurophysiology : official journal of the International Federation of Clinical Neurophysiology* 2001;265-274-112.
- 8 D. J. Serrien, A. C. Nirkko, K. O. Lovblad, M. Wiesendanger. Damage to the parietal lobe impairs bimanual coordination. *Neuroreport* 2001;2721-2724-12.
- 9 S. P. Swinnen, N. Wenderoth. Two hands, one brain: cognitive neuroscience of bimanual skill. *Trends Cogn Sci* 2004;18-25-8.
- 10 M. Oliveri, P. M. Rossini, R. Traversa, P. Cicinelli, M. M. Filippi, P. Pasqualetti, F. Tomaiuolo, C. Caltagirone. Left frontal transcranial magnetic stimulation reduces contralesional extinction in patients with unilateral right brain damage. *Brain : a journal of neurology* 1999;1731-1739-122 (Pt 9).
- 11 B. Fierro, F. Brighina, M. Oliveri, A. Piazza, V. La Bua, D. Buffa, E. Bisiach. Contralateral neglect induced by right posterior parietal rTMS in healthy subjects. *Neuroreport* 2000;1519-1521-11.
- 12 C. C. Hilgetag. Spatial neglect and paradoxical lesion effects in the cat - a model based on midbrain connectivity. *Neurocomputing* 2000;793-799-32-33
- 13 M. Di Stefano, M. Morelli, C. A. Marzi, G. Berlucchi. Hemispheric control of unilateral and bilateral movements of proximal and distal parts of the arm as inferred from simple reaction time to lateralized light stimuli in man. *Experimental Brain Research* 1980;197-204-38.
- 14 M. Kerr, R. Mingay, A. Elithorn. Cerebral Dominance in Reaction Time Responses. *Br J Psychol* 1963;325-336-54.
- 15 T. Ohtsuki. Increase in simple reaction time of knee extension induced by simultaneous bilateral performance. *Perceptual and motor skills* 1981;27-30-53.
- 16 B. Steenbergen, W. Hulstijn, A. de Vries, M. Berger. Bimanual movement coordination in spastic hemiparesis. *Experimental brain research. Experimentelle Hirnforschung. Experimentation cerebrale* 1996;91-98-110.
- 17 Y. Taniguchi. Effect of practice in bilateral and unilateral reaction-time tasks. *Perceptual and motor skills* 1999;99-109-88.
- 18 T. Ohtsuki. Decrease in human voluntary isometric arm strength induced by simultaneous bilateral exertion. *Behavioural brain research* 1983;165-178-7.

- 19 T. Ohtsuki. Change in strength, speed, and reaction time induced by simultaneous bilateral muscular activity. In: Swinnen SP, Massion J, Heuer H, Casaer P. Academic Press. New York. 1994.p 259-74.
- 20 M. I. Garry,I. M. Franks. Reaction time differences in spatially constrained bilateral and unilateral movements. Experimental brain research. Experimentelle Hirnforschung. Experimentation cerebrale 2000;236-243-131.
- 21 Y. Taniguchi, B. Burle, F. Vidal,M. Bonnet. Deficit in motor cortical activity for simultaneous bimanual responses. Experimental brain research. Experimentelle Hirnforschung. Experimentation cerebrale 2001;259-268-137.

Figure captions

Figure 1. Pre-operative FLAIR-weighted axial and post-operative T1-weighted axial MRI for patient P1 (left panel), pre- and postoperative FLAIR-weighted axial MRI for P2 (middle panel) and pre-operative T2-weighted axial and post-operative FLAIR-weighted axial MRI for P3 (right panel), showing an invasion (upper row) and a resection (lower row) of the parietal lobe. Neurological conventions (only for this figure).

Figure 2. Mean RTs and standard deviation (vertical lines) for the right and left hands in the two unimanual (RE and LE) and the bimanual (RLE) externally conditions, for P1, P2, P3 and the control group.

Figure 3. Mean delta scores \pm standard deviation (vertical lines) in the RLE and RLI conditions, for P1, P2, P3 and the control group. Delta score is positive when the right index finger moved before the left one and negative when the left index move first.

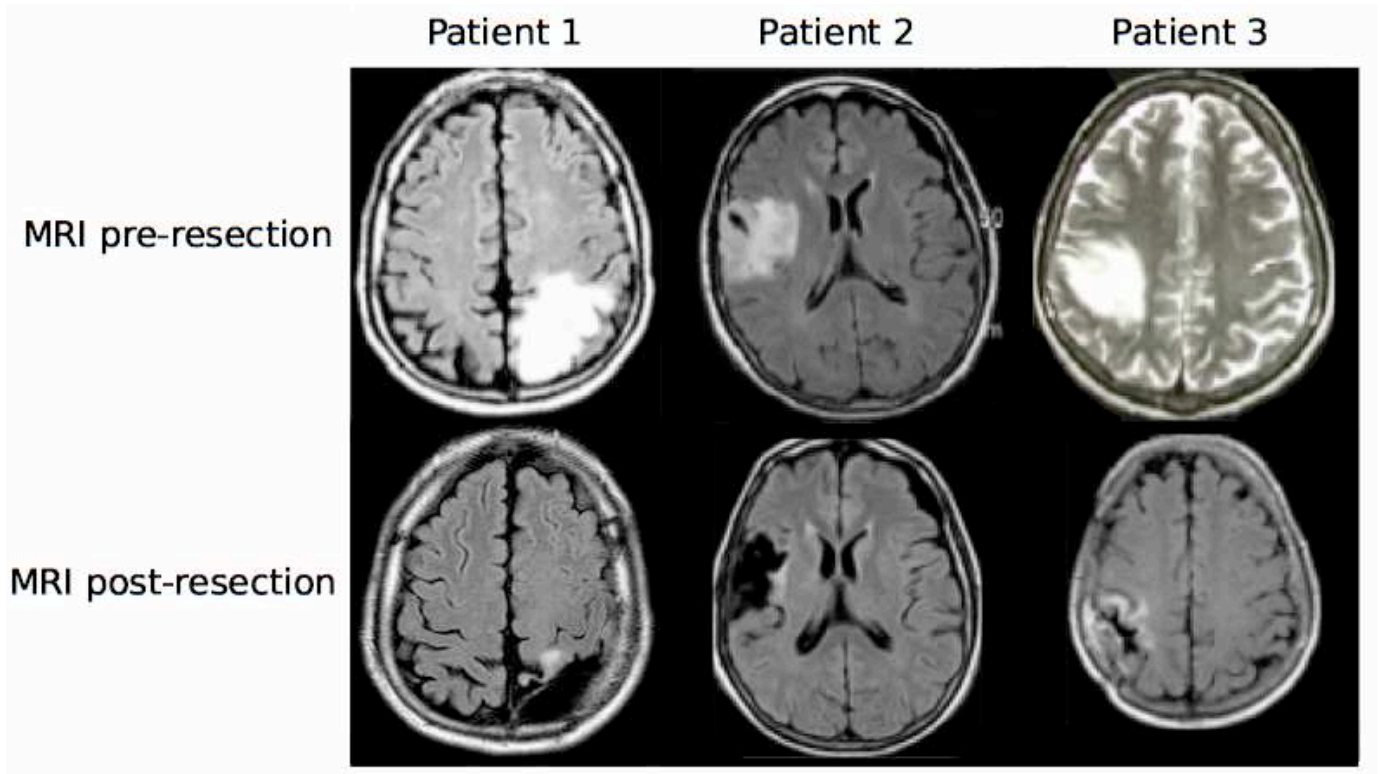


Figure 1

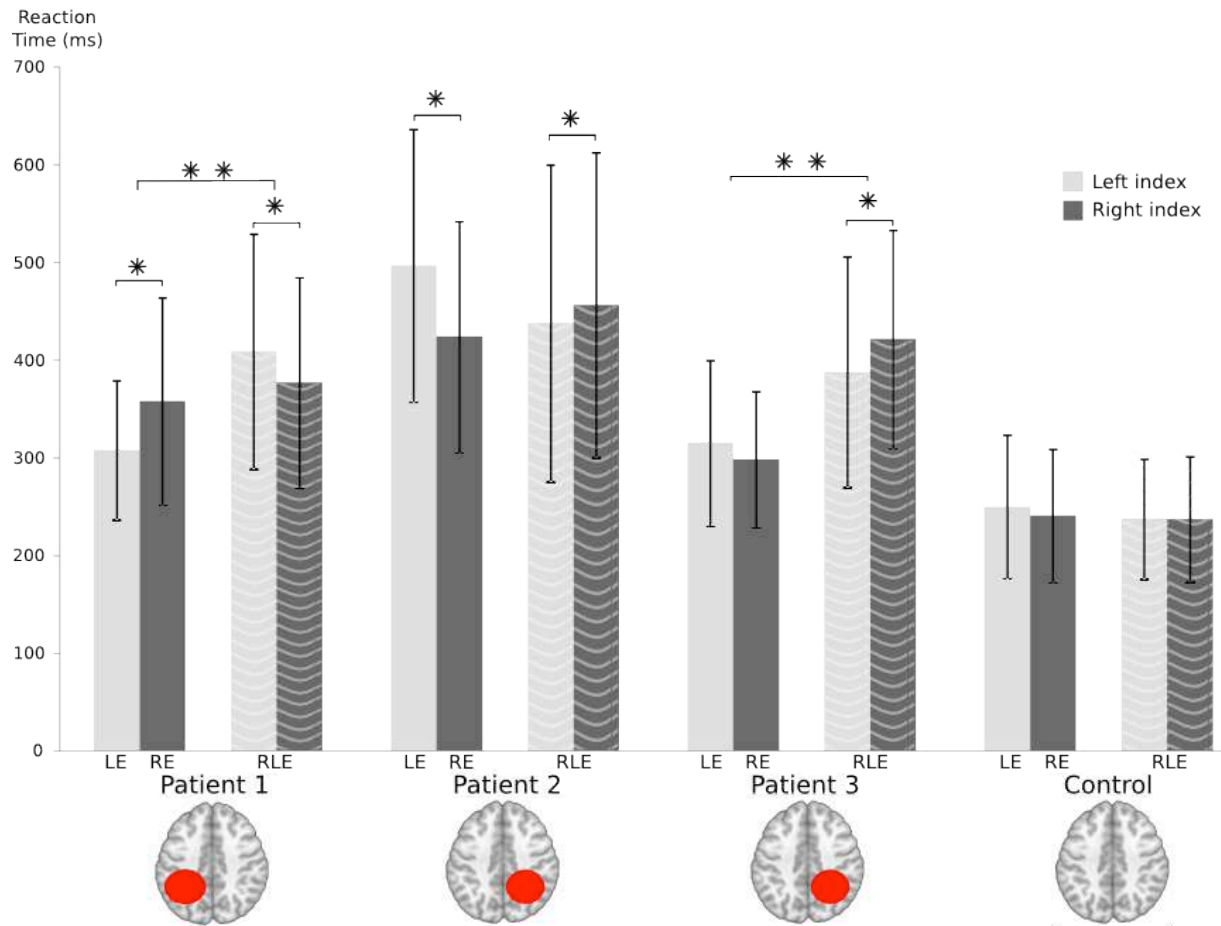


Figure 2

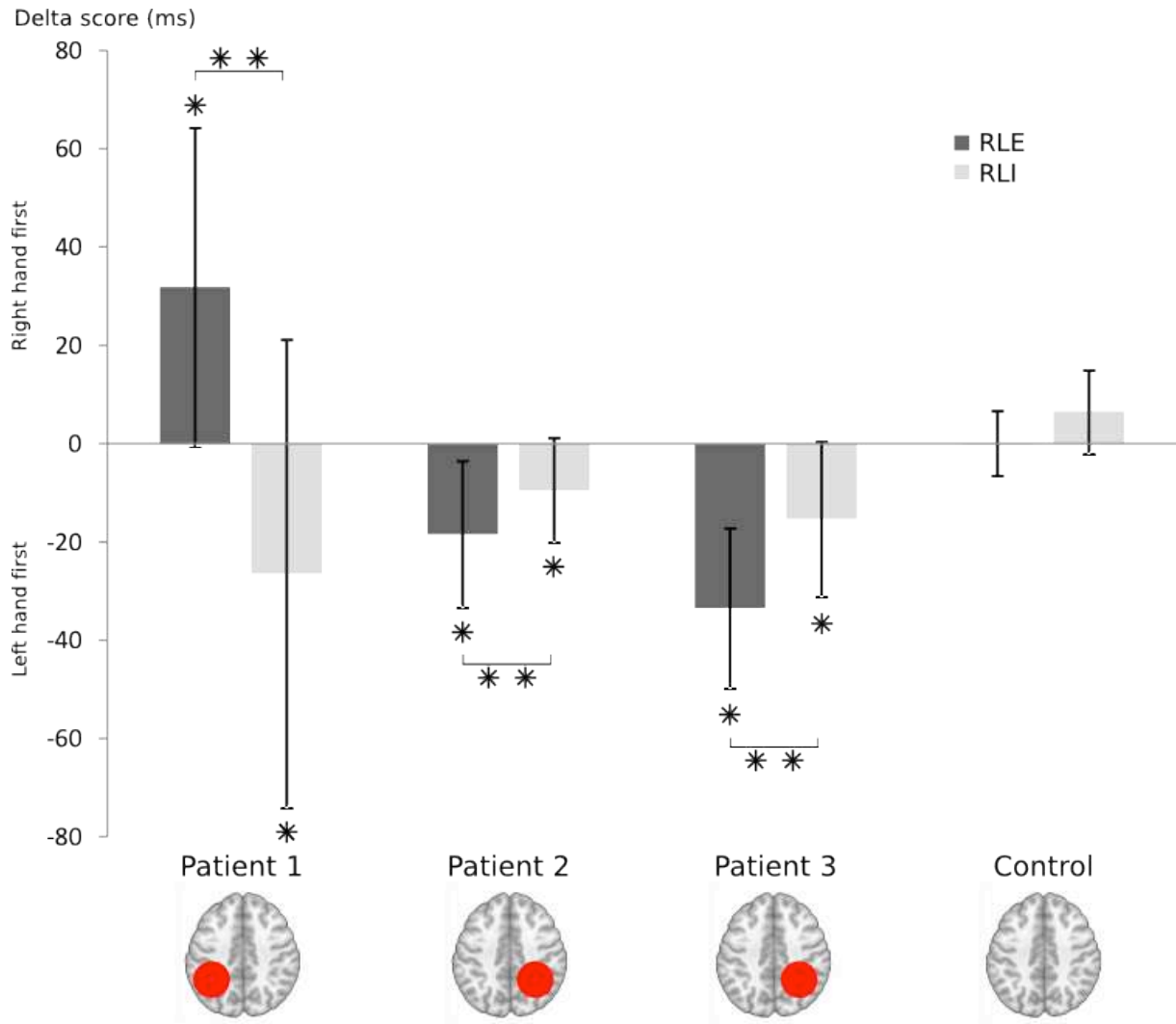


Figure 3