



**HAL**  
open science

## Robot-guided osteotomy in fibula free flap mandibular reconstruction: a preclinical study

Marie de Boutray, Lénaïc Cuau, Michael Ohayon, Renaud Garrel, Philippe Poignet, Nabil Zemiti

### ► To cite this version:

Marie de Boutray, Lénaïc Cuau, Michael Ohayon, Renaud Garrel, Philippe Poignet, et al.. Robot-guided osteotomy in fibula free flap mandibular reconstruction: a preclinical study. *International Journal of Oral and Maxillofacial Surgery*, 2024, 53 (4), pp.343-346. 10.1016/j.ijom.2023.07.010 . lirmm-04188126

**HAL Id: lirmm-04188126**

**<https://hal-lirmm.ccsd.cnrs.fr/lirmm-04188126>**

Submitted on 13 Mar 2024

**HAL** is a multi-disciplinary open access archive for the deposit and dissemination of scientific research documents, whether they are published or not. The documents may come from teaching and research institutions in France or abroad, or from public or private research centers.

L'archive ouverte pluridisciplinaire **HAL**, est destinée au dépôt et à la diffusion de documents scientifiques de niveau recherche, publiés ou non, émanant des établissements d'enseignement et de recherche français ou étrangers, des laboratoires publics ou privés.

## Technical Note Robotic Surgery

# Robot-guided osteotomy in fibula free flap mandibular reconstruction: a preclinical study

M. de Boutray<sup>a,b</sup>, L. Cuau<sup>b</sup>,  
 M. Ohayon<sup>b</sup>, R. Garrel<sup>a</sup>, P. Poignet<sup>b</sup>,  
 N. Zemiti<sup>b</sup>

<sup>a</sup>ENT Department, Neck Surgery and Maxillofacial Surgery, Gui de Chauliac University Hospital, Montpellier University School of Medicine, Montpellier, France;  
<sup>b</sup>LIRMM, University of Montpellier, CNRS, Montpellier, France

M. de Boutray, L. Cuau, M. Ohayon, R. Garrel, P. Poignet, N. Zemiti: Robot-guided osteotomy in fibula free flap mandibular reconstruction: a preclinical study. *Int. J. Oral Maxillofac. Surg.* 2021; xx: 1–4. © 2023 International Association of Oral and Maxillofacial Surgeons. Published by Elsevier Inc. All rights reserved.

**Abstract.** Various methods currently exist to guide fibular osteotomy positioning in fibula free flap mandibular reconstruction, but patient-specific navigation methods and cutting guides require experience, and may be time-consuming and/or expensive. This study describes a robot-guided osteotomy technique for mandible reconstruction using a fibula free flap according to virtual preoperative planning. The method was assessed on five 3D-printed models and a cadaveric model. The precision of the robot-guided osteotomy was evaluated by measuring the deviations between the lengths and angles of the fragments obtained and those of the virtual planning. The average deviation of the anterior and posterior crest lengths was  $0.42 \pm 0.29$  mm for the 3D-printed models and  $1.00 \pm 0.53$  mm for the cadaveric model. The average angle deviation was  $1.90 \pm 1.22^\circ$  and  $1.94 \pm 0.69^\circ$  for the 3D-printed and cadaveric models, respectively. The results of this preclinical study revealed that fibular osteotomy positioning guidance using a robot-positioned cutting guide may be a precise, easy-to-use technique that could be tailored for fibula free flap mandibular reconstruction.

**Keywords:** Free tissue flaps; Mandibular reconstruction; Computer-assisted surgery; Robotic surgical procedures; Neuronavigation; Osteotomy; Mandible; Fibula.

Accepted for publication 25 July 2023  
 Available online xxxx

In recent years, technological research towards guiding fibula free flap (FFF) osteotomy, conformation, and fixation in mandible reconstruction has increased, with the aim of reducing the long learning curve necessary for this technique.<sup>1</sup> Current solutions mainly include intraoperative surgical navigation,<sup>2,3</sup> computer-aided design and

manufacturing (CAD/CAM), and patient-specific cutting guides.

Robotic-assisted surgery is used in many fields to help in precise surgical procedures, but seldom in maxillofacial and reconstructive surgery.<sup>4,5</sup> Yet robotic-assisted surgery is an excellent means to overcome the constraints of surgical navigation and patient-specific

guides. Therefore, investigators at Montpellier University School of Medicine have focused on developing a FFF osteotomy guide that is robot-positioned after virtual osteotomy planning. The aim of this robot-positioned guide is to help in accurate positioning and orientation of the surgical saw on the fibula, while the surgeon

maintains control of the pressure applied to the saw and its depth positioning, thereby ensuring preservation of the underlying vascular pedicle. The position of the fibular osteotomy is determined according to preoperative patient-specific image-based surgical planning. The advantage of this method compared to currently used guidance techniques (i.e. navigation and CAD/CAM guides) is that it can be adapted at any time, even during surgery, in the event of tumour progression or an unforeseen intercurrent intraoperative issue requiring adjustment of the initial planning.

This report describes the use of this robot-guided osteotomy technique for FFF mandibular reconstruction on three-dimensionally (3D)-printed fibula models and on a cadaveric fibula.

## Technique


### Virtual planning of the osteotomy position

Images of a human patient leg (for the 3D-printed fibula model) and a cadaveric leg (for the cadaveric fibula model) in DICOM format were manually segmented to generate a virtual 3D fibula model for each of them. The segmentation was achieved using 3D Slicer open source software (version 4.10.1; [www.slicer.org](http://www.slicer.org)). Polycarbonate was used for the 3D-printed fibula model.

The positions and orientations of the 3D-printed and cadaveric fibula model osteotomies were virtually planned in SolidWorks software (SolidWorks 3D CAD, 2019; Dassault Systèmes SolidWorks, Waltham, MA, USA). The cutting planes were planar sections intersecting the fibula models and were defined by three points located on their surface (Supplementary Material Fig. S1).

### Navigation and calibration

An optical fusionTrack 500 tracking camera and system (Atracsys, Puidoux, Switzerland; 0.09 mm RMS accuracy up to 2 m away) was used for infrared navigation. A Panda co-manipulated 7 degrees-of-freedom robot arm was used (Franka Emika, Munich, Germany). The Panda robot and fibula models (3D-printed and cadaveric) were equipped with a fixed tracking marker that allowed the tracking camera to locate them in the marker frame (Fig. 1; Supplementary Material Fig. S2).



*Fig. 1.* Robot-guided fibular osteotomy setup. The osteotomy guide is fixed as the robot arm end-effector, which holds a tracking marker. Once the osteotomy guide is positioned by the robot, the saw can be placed in the exact position and orientation on the fibula model, which also holds a tracking marker so that the robot can replace the guide in the case of fibula displacement.

The fibula models were registered and tracked according to the procedure described in a previous study<sup>6</sup>: registration initialization was achieved after tracking tool calibration, followed by digitization of the fibula surface in order to align the digitized point cloud on the virtual computed tomography (CT)-scanned fibula mesh surface.

### Robotic positioning of the guide and osteotomies

The position of the robot-held cutting guide on the fibula was then defined by the description of the osteotomy planes in the robot end-effector frame according to the fibula model position.

The cutting guide was designed with a slot to be positioned as close as possible to the fibula, so as to enable precise saw blade insertion (Fig. 1). An oscillating saw (RemB; Stryker, Kalamazoo MI, USA) with a 0.380 mm thick saw blade was used. Hence a 0.85 mm thick slot was designed so that the saw blade would fit in the slot while providing leeway for the blade to vibrate without friction on the slot edges. The guide was irrigated during cutting to avoid overheating and therefore possible melting of the polycarbonate guide during the iterative cutting process.

### Evaluation of performance

The performance of the robot-guided osteotomy procedure was assessed through double evaluation of the

deviations between the lengths and angles of the osteotomized fragments and the virtually planned fragments. The osteotomized fragments were CT-scanned and manually segmented using 3D Slicer software. The lengths of the anterior and posterior crests of the digitized mesh, as well as the angles between the crests and the osteotomy planes (Fig. 2) were measured by two different evaluators based on the point-picking distance and angle calculator available in CloudCompare open source software (version 2.12.0; [www.cloudcompare.org](http://www.cloudcompare.org)).

The robot-guided osteotomy technique was applied on five 3D-printed fibulas and on one cadaveric leg. The initialization point acquisition, bone surface reconstruction, and osteotomy procedures were performed by a maxillofacial surgeon. All virtual procedures were completed by the same engineer.

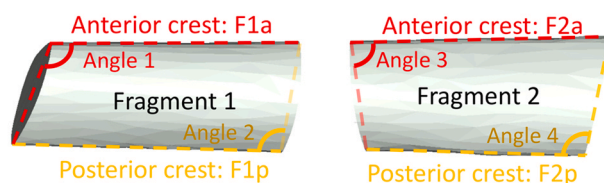
The mean  $\pm$  standard deviation completion time of the procedure on the 3D-printed models (including calibration, registration, robotic iterative guide positioning, and the four osteotomies) was  $16.1 \pm 0.35$  min. The model length and angle measurements are reported in Table 1. The average deviation of the crest lengths was  $0.42 \pm 0.29$  mm and the average angle deviation was  $1.90 \pm 1.22^\circ$ .

The registration procedure was implemented five times on the cadaveric model, with an average completion time of  $4.74 \pm 1.1$  min; the osteotomy procedure was achieved once. The whole procedure completion time including calibration, target marker fixation, registration, and osteotomy completion on the cadaveric model was  $18.8 \pm 1.1$  min. The mean length deviation was  $1.00 \pm 0.53$  mm and the mean angle deviation was  $1.94 \pm 0.69^\circ$  (Table 2).

## Discussion

The robotic guidance method described here has several advantages over the techniques generally used for FFF reconstruction and over recently reported technological advances. It enables more precise cutting than a conformation without guidance (0.42 mm with the 3D-printed models and 1.00 mm with the cadaveric model in this study, as compared to  $> 2$  mm with the freehand technique<sup>4,7</sup>), and the associated learning curve would probably be much faster. This technique using a robot-positioned cutting guide also allows the surgeon to maintain perfect fibular

### 3D-printed CT-scanned model



### Cadaveric CT-scanned model

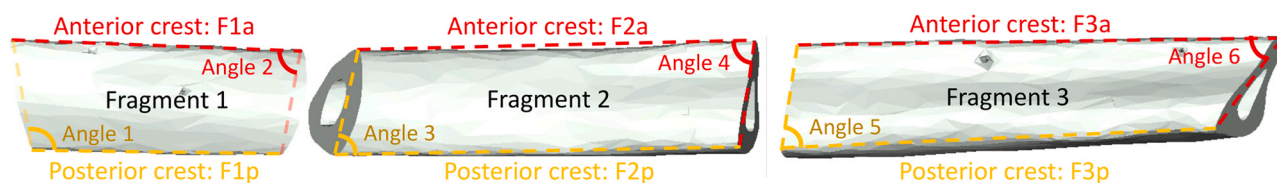


Fig. 2. Fibula fragment length and angle measurements. The fragments obtained after robot-guided osteotomies on both the 3D-printed and cadaveric models were CT-scanned and segmented to obtain a mesh version of them. These meshes were compared to the virtually planned mesh by measuring the anterior and posterior crest lengths and the angles between these crests and the parallel to the osteotomy planes joining the two crests.

osteotomy control in terms of the pressure applied to the saw and depth of the cut, thereby ensuring preservation of the fibula pedicle, in the same way as with a patient-specific cutting guide. Indeed, the present authors consider that it is preferable for the surgeon to perform osteotomies using a robot-positioned cutting guide than having the osteotomy performed by a robot handling the surgical saw.<sup>4,5</sup> Several studies on haptic guidance are under way, which could also be an interesting option to combine with robot-aided saw positioning in surgeon-controlled operations.<sup>8</sup> Compared to navigation only, the technique presented here has the advantage of requiring almost no learning curve. Indeed, saw positioning in 3D space based on a two-dimensional navigation system is a difficult task requiring substantial training. It would be interesting to compare the learning curves associated with these two guidance techniques. Similarly, guidance with augmented reality technologies could be compared

to the current technique in terms of accuracy, ease of use, and learning curve.

Moreover, this method was found to have the same range of accuracy as techniques involving osteotomy guidance using patient-specific guides, while having two further key advantages: there is no manufacturing time related to the design and external printing of the material, and it is also highly modifiable to meet needs in the event of rapid tumour progression. The precision of this method was 0.42 mm for the 3D-printed models and 1.00 mm for the cadaveric model, which is compatible with medical requirements related to mandibular reconstruction.<sup>9</sup> The complete procedure completion time was an average of 18.8 min for the cadaveric procedure and 16.1 min for the five 3D-printed model procedures. This is longer than reported for a conformation without guidance and for a patient-specific guidance procedure,<sup>7</sup> but it is probably equivalent to or shorter than the completion time of a procedure with navigation guidance,

especially when performed by an inexperienced user. The decrease in surgery time, including the flap conformation time, implies that there would be fewer postoperative complications and expenses. Future studies should therefore focus on the operating time related to the guidance procedure and its economic implications.

There are very few reported studies on robotic guidance of osteotomies in FFF mandibular reconstruction: only three published studies reporting similar results to those of the current study, but using different techniques, were identified. One used a CARLO laser robot to perform fibular and mandibular osteotomies on cadaveric models.<sup>10</sup> The second study reported the results obtained using a FFF positioning robot to correct a mandible defect in a 3D-printed model and an animal model.<sup>4</sup> The accuracy ranged from 1 mm to 2 mm, as compared to > 2 mm with the freehand technique. In that study, the fibular osteotomy was not robot-guided (only the mandible

Table 1. Length and angle deviations of each osteotomized fragment of the five 3D-printed fibula models compared to the corresponding virtually planned fragments; mean  $\pm$  standard deviation in millimetres or degrees.

Model	F1 anterior	F1 posterior	F2 anterior	F2 posterior	Angle 1	Angle 2	Angle 3	Angle 4
#1	0.39 $\pm$ 0.22	0.61 $\pm$ 0.39	0.09 $\pm$ 0.05	0.60 $\pm$ 0.35	0.50 $\pm$ 0.29	2.40 $\pm$ 0.39	2.05 $\pm$ 0.19	0.75 $\pm$ 0.78
#2	0.47 $\pm$ 0.23	0.94 $\pm$ 0.00	0.88 $\pm$ 0.30	0.20 $\pm$ 0.07	0.90 $\pm$ 0.57	1.45 $\pm$ 0.49	4.20 $\pm$ 0.57	0.90 $\pm$ 0.00
#3	0.02 $\pm$ 0.01	0.47 $\pm$ 0.13	0.86 $\pm$ 0.14	0.25 $\pm$ 0.29	0.95 $\pm$ 0.07	2.85 $\pm$ 0.21	2.70 $\pm$ 0.42	0.65 $\pm$ 0.07
#4	0.08 $\pm$ 0.07	0.28 $\pm$ 0.05	0.78 $\pm$ 0.02	0.39 $\pm$ 0.23	1.70 $\pm$ 0.99	4.30 $\pm$ 0.99	3.25 $\pm$ 0.50	0.70 $\pm$ 0.14
#5	0.40 $\pm$ 0.04	0.22 $\pm$ 0.08	0.29 $\pm$ 0.18	0.15 $\pm$ 0.15	0.65 $\pm$ 0.50	2.20 $\pm$ 1.56	3.45 $\pm$ 0.50	1.35 $\pm$ 0.07
Overall	0.27 $\pm$ 0.20	0.50 $\pm$ 0.29	0.58 $\pm$ 0.37	0.32 $\pm$ 0.18	0.94 $\pm$ 0.46	2.64 $\pm$ 1.05	3.13 $\pm$ 0.80	0.87 $\pm$ 0.28

F, fragment.



Table 2. Length and angle deviations of each osteotomized fragment of the cadaveric fibula model compared to the corresponding virtually planned fragments; mean  $\pm$  standard deviation in millimetres or degrees.

Fragments	F1 anterior	F1 posterior	F2 anterior	F2 posterior	F3 anterior	F3 posterior	Overall
	0.85 $\pm$ 0.11	1.06 $\pm$ 0.23	0.76 $\pm$ 0.22	0.25 $\pm$ 0.16	1.29 $\pm$ 0.60	1.82 $\pm$ 0.11	1.00 $\pm$ 0.53
Angles	Angle 1	Angle 2	Angle 3	Angle 4	Angle 5	Angle 6	Overall
	2.04 $\pm$ 1.04	0.96 $\pm$ 0.53	3.05 $\pm$ 0.44	2.12 $\pm$ 0.14	1.63 $\pm$ 0.03	1.83 $\pm$ 0.32	1.94 $\pm$ 0.69

F, fragment.

osteotomy was). The third study reported fibular osteotomies performed using a robotic-positioned saw on three 3D-printed models.<sup>5</sup> The linear and angular accuracy was 1.3 mm and 4.2°, respectively. In that study, the saw was carried and manipulated directly by the robot.

Further studies are required to determine whether robot-guided fibular osteotomy outcomes vary between users and whether there is a learning curve. Hence, it would be essential to objectively compare this guidance technique with other existing techniques, i.e. patient-specific guides, ‘in-house’ guides, and navigation. This preclinical study on the use of a robot-positioned fibular osteotomy guide highlights the potential of this technique for achieving excellent precision with regard to positioning and orienting the fibular cuts based on virtual planning.

#### Ethical approval

Not required.

#### Patient consent

Not required.

#### Funding

This study was supported in part by the French National Research Agency (Agence Nationale pour la Recherche, ANR) within the Investissements d’Avenir programme (Labex CAMI, ANR-11-LABX0004; Labex NUMEV, ANR-10-LABX-20, and the ROBOTEX Equipex, ANR-10-EQPX-44-01).

#### Conflict of interests

No competing interests.

#### Appendix A. Supporting information

Supplementary data associated with this article can be found in the online version at [doi:10.1016/j.ijom.2023.07.010](https://doi.org/10.1016/j.ijom.2023.07.010).

#### References

- Blackwell KE, Brown MT, Gonzalez D. Overcoming the learning curve in microvascular head and neck reconstruction. *Arch Otolaryngol Head Neck Surg* 1997; **123**:1332–5. <https://doi.org/10.1001/archotol.1997.01900120082013>
- Shan XF, Chen HM, Liang J, Huang JW, Zhang L, Cai ZG, Guo C. Surgical navigation-assisted mandibular reconstruction with fibula flaps. *Int J Oral Maxillofac Surg* 2016; **45**:448–53. <https://doi.org/10.1016/j.ijom.2015.08.1006>
- Pietruski P, Majak M, Świątek-Najwer E, Zuk M, Popek M. Navigation-guided fibula free flap for mandibular reconstruction: a proof of concept study. *J Plast Reconstr Aesthet Surg* 2019; **72**:572–80. <https://doi.org/10.1016/j.bjps.2019.01.026>
- Zhu JH, Deng J, Liu XJ, Wang J, Guo YX, Guo CB. Prospects of robot-assisted mandibular reconstruction with fibula flap: comparison with a computer-assisted navigation system and freehand technique. *J Reconstr Microsurg* 2016; **32**:661–9. <https://doi.org/10.1055/s-0036-1584805>
- Chao AH, Weimer K, Raczowsky J, Zhang Y, Kunze M, Cody D, Selber JC, Hanasono M, Skoracki R. Pre-programmed robotic osteotomies for fibula free flap mandible reconstruction: a pre-clinical investigation. *Microsurgery* 2016; **36**:246–9. <https://doi.org/10.1002/micr.30013>
- de Boutray M, Cavalcanti Santos J, Bourgeade A, Ohayon M, Chammas PE, Garrel R, Poinet P, Zemiti N. Fibular registration using surface matching in navigation-guided osteotomies: a proof of concept study on 3D-printed models. *Int J Comput Assist Radiol Surg* 2022; **17**:1321–31. <https://doi.org/10.1007/s11548-022-02608-0>
- Zhang L, Liu Z, Li B, Yu H, Shen SG, Wang X. Evaluation of computer-assisted mandibular reconstruction with vascularized fibular flap compared to conventional surgery. *Oral Surg Oral Med Oral Pathol Oral Radiol* 2016; **121**:139–48. <https://doi.org/10.1016/j.oooo.2015.10.005>
- Cheng L, Carriere J, Piwowarczyk J, Aalto D, Zemiti N, de Boutray M, Tavakoli M. Admittance-controlled robotic assistant for fibula osteotomies in mandible reconstruction surgery. *Adv Intell Syst* 2021; **3**:2000158. <https://doi.org/10.1002/aisy.202000158>
- Lai Y, Wang C, Mao C, Lu M, Ouyang Q, Fang Y, Cai Z, Chen W. Mandible reconstruction with free fibula flaps: accuracy of a cost-effective modified semicomputer-assisted surgery compared with computer-assisted surgery—a retrospective study. *J Craniomaxillofac Surg* 2022; **50**:274–80. <https://doi.org/10.1016/j.jcms.2021.12.004>
- Augello M, Baetscher C, Segesser M, Zeilhofer HF, Cattin P, Juergens P. Performing partial mandibular resection, fibula free flap reconstruction and mid-facial osteotomies with a cold ablation and robot-guided Er:YAG laser osteotome (CARLO®)—a study on applicability and effectiveness in human cadavers. *J Craniomaxillofac Surg* 2018; **46**:1850–5. <https://doi.org/10.1016/j.jcms.2018.08.001>

Correspondence to: Unité de Chirurgie Maxillo-faciale et Chirurgie Reconstructrice de la Face  
Département d’ORL CMF  
CHU Gui de Chauliac  
80 av Augustin Fliche  
34295 Montpellier  
France. Fax: +33 4 67 33 68 41.  
E-mail: [m-deboutray@chu-montpellier.fr](mailto:m-deboutray@chu-montpellier.fr)