



HAL
open science

Anatomical variations of interest for posterior nasal nerve cryotherapy in the treatment of chronic rhinitis: A radioanatomic study

Juliette Sliman, Florent Carsuzaa, Lei Tanaka, Patrice Gallet, Pierre-Olivier Moser, Guillaume Captier, Valentin Favier

► To cite this version:

Juliette Sliman, Florent Carsuzaa, Lei Tanaka, Patrice Gallet, Pierre-Olivier Moser, et al.. Anatomical variations of interest for posterior nasal nerve cryotherapy in the treatment of chronic rhinitis: A radioanatomic study. *International Forum of Allergy and Rhinology*, 2023, 14 (5), pp.995-998. 10.1002/alr.23305 . lirmm-04696706

HAL Id: lirmm-04696706

<https://hal-lirmm.ccsd.cnrs.fr/lirmm-04696706>

Submitted on 13 Sep 2024

HAL is a multi-disciplinary open access archive for the deposit and dissemination of scientific research documents, whether they are published or not. The documents may come from teaching and research institutions in France or abroad, or from public or private research centers.



L'archive ouverte pluridisciplinaire **HAL**, est destinée au dépôt et à la diffusion de documents scientifiques de niveau recherche, publiés ou non, émanant des établissements d'enseignement et de recherche français ou étrangers, des laboratoires publics ou privés.



Distributed under a Creative Commons Attribution - NonCommercial - NoDerivatives 4.0 International License

RESEARCH NOTE

Anatomical variations of interest for posterior nasal nerve cryotherapy in the treatment of chronic rhinitis: A radioanatomic study

Juliette Sliman MD¹ | Florent Carsuzaa MD^{2,3}  | Lei Tanaka MD⁴ |
 Patrice Gallet MD, PhD^{5,6,7} | Pierre-Olivier Moser MD⁸ | Guillaume Captier MD,
 PhD^{9,10} | Valentin Favier MD, PhD^{1,10} 

¹Department of Otolaryngology Head and Neck Surgery, Gui de Chauliac Hospital, University Hospital of Montpellier, Montpellier, France

²Service ORL, Chirurgie Cervico-Maxillo-Faciale et Audiophonologie, Centre Hospitalier Universitaire de Poitiers, Poitiers, France

³Laboratoire Inflammation Tissus Epithéliaux et Cytokines, UR15560, Université de Poitiers, Poitiers, France

⁴Service d'Orl et Chirurgie Cervico-Faciale, Assistance Publique-Hôpitaux de Paris, Université Paris-Saclay, Hôpital Bicêtre, le Kremlin-Bicêtre, France

⁵Department of ENT, Regional University Hospital of Nancy, University of Lorraine, Vandoeuvre-lès-Nancy, France

⁶Virtual Hospital of Lorraine, University of Lorraine, Vandoeuvre-lès-Nancy, France

⁷NGERE, INSERM U1256 Lab, University of Lorraine, Vandoeuvre-lès-Nancy, France

⁸Department of Neurosurgery, Gui de Chauliac Hospital, University Hospital of Montpellier, Montpellier, France

⁹Laboratory of Anatomy, Faculty of Medicine of Montpellier-Nîmes, Montpellier University, Montpellier, France

¹⁰Research-Team ICAR, Laboratory of Computer Science, Robotics and Microelectronics of Montpellier, Montpellier University, French National Centre for Scientific Research, Montpellier, France

Correspondence

Valentin Favier, Département d'ORL,
 Chirurgie Cervico-Faciale et
 Maxilla-Faciale, Hôpital Gui de Chauliac,
 CHU Montpellier, 80 Avenue Augustin
 Fliche, 34295 Montpellier, France.
 Email: valentin_favier@hotmail.com

KEYWORDS

radiology, rhinitis, sinus anatomy

Key Points

1. An unfavorable insertion of the middle turbinate for cryotherapy was present in 74.2% of cases.
2. Placing cryoprobe 15–30 mm above the nasal floor targets the nerves in 95.8% of cases.
3. Centering the cryoprobe 38 mm behind the inferior turbinate axilla targets the nerves in 94.6% of cases.

1 | INTRODUCTION

Posterior nasal nerve (PNN) cryotherapy aims to treat chronic refractory rhinitis (CRR) using a transmucosal application of a cryogen. PNN comes from the pterygoid canal nerve (formerly called Vidian nerve) and emerges in

the nasal fossa through the sphenopalatine foramen (SPF). PNN regulates the secretions of the palatine and nasal mucosa.¹

PNN cryotherapy requires targeting the SPF area without mucosal dissection. Variations in endoscopic anatomical landmarks² might contribute to the relatively high

This is an open access article under the terms of the [Creative Commons Attribution-NonCommercial-NoDerivs](https://creativecommons.org/licenses/by-nc-nd/4.0/) License, which permits use and distribution in any medium, provided the original work is properly cited, the use is non-commercial and no modifications or adaptations are made.

© 2023 The Authors. *International Forum of Allergy & Rhinology* published by Wiley Periodicals LLC on behalf of American Academy of Otolaryngic Allergy and American Rhinologic Society.

failure rate (25%–33%).^{3–5} Fan et al.⁶ suggested a possible link between an unfavorable middle turbinate (MT) position (i.e., in front of the SPF) and the failure of PNN transmucosal procedures for CRR.

However, their study only focused on a retrospective analysis of patients who underwent a PNN procedure. There remains a gap in knowledge regarding the prevalence of unfavorable MT positions in the general population and a lack of well-defined surgical landmarks and measurement criteria.

The objectives of this radioanatomic study were (1) to describe the anatomical variations of the insertion of MT related to the SPF area in the general population and (2) to identify computed tomography (CT) scan landmarks and measurements that can be used pre- and intraoperatively to guide the surgeon in the application of the cryogen, taking into consideration the dimension of the cryoprobe balloon (CB) (15 × 15 mm) of the ClariFix device (Stryker).

2 | METHODS

A database of 157 CT scans from adults, obtained during routine hematological screening and free from sinonasal diseases, was anonymized and used for this study with Institutional Review Board approval (2020PI160). Both sides of CT scans were analyzed by two otolaryngologists, with the following landmarks identified using itk-SNAP software:⁷

- Anterior nasal spine
- Inferior turbinate axilla (ITA) insertion
- Anteromedial point of the tubal orifice
- Posterior nasal spine (PNS), to approximate the level of the nasal floor in the vertical dimension
- SPF
- Mode of insertion of the MT in relation to the SPF: favorable when the MT was inserted behind the SPF, unfavorable in other cases

Anatomical distances between landmarks were calculated using MS Excel Software. Mean distances were described with standard deviation and minimal–maximal values.

The distances were compared to the dimension of the CB to provide information for clinical practice.

3 | RESULTS

The CT scan database included 84 women (53.5%) and 73 men (46.5%), with a mean age of 50.8 ± 14.5 [18–83] years.

3.1 | Pattern of insertion of MT in relation to the SPF

Among the 314 CT scan sides analyzed, 233 (74.2%) MT insertions were deemed unfavorable and 81 (25.8%) were favorable. In nine patients (5.7%), the type of MT insertion was different between right and left sides (Supporting Information S1).

3.2 | Anatomical distances for cryogen application

The anatomical distances of interest are summarized in Table 1.

The SPF was located 38.3 ± 4 mm [23.8–52.4] behind the ITA insertion and 22.6 ± 3.6 mm [18.2–29.3] above the PNS on the lateral nasal wall.

Positioning the cryoprobe 15 mm above the nasal floor covers an area extending 15–30 mm upward and theoretically achieves a success rate of 95.9% ($n = 301/314$) in targeting the SPF in the vertical dimension. Likewise, positioning the center of the CB at 38.3 mm from the ITA in the anteroposterior dimensions results in an application area of 30.8–45.8 mm, with a theoretical success rate of 94.6% ($n = 297/314$) (Figure 1). Taken together, these conditions yield a theoretical success rate of 90.8% ($n = 285/314$) (Supporting Information S2).

The mean distance between the SPF and the most anteromedial point of the tubal orifice was 18.2 ± 42.1 mm [9.6; 29.6]. In the studied population, this distance was inferior to the diameter of the CB (15 mm) in 30 sides (9.5%) (Figure 1).

4 | DISCUSSION

PNN cryotherapy is a minimally invasive option for the treatment of CRR. Interindividual anatomical variability can explain part of failure rate. Fan et al.⁶ demonstrated a higher prevalence of unfavorable MT insertion in cases of cryotherapy/radiofrequency failure compared to success (90.9% vs. 55%). We found 74.2% of unfavorable MT. In our opinion, MT insertion should be assessed preoperatively, but other factors could be implicated in treatment's failure, such as the symptoms motivating the procedure. Schmale et al.⁸ highlighted the importance of preoperative endoscopy and CT scan to optimize cryotherapy indications due to the overlap of symptoms between CRR and chronic rhinosinusitis.

However, CRR diagnosis and management remain based on clinical findings. Thus, the placement of CB

TABLE 1 Descriptive analysis of anatomical distances of interest.

| Anatomical distance | Definition | Mean [standard deviation] (mm) | Minimal–maximal (mm) | Clinical significance |
|--|--|--------------------------------|----------------------|---|
| Distances in the transverse direction | | | | |
| Width of the nasal cavity | Between SPF and PNS in the transverse direction (x coordinates) | 13.3 [2.2] | 7.9–19.7 | Workspace in the transverse direction |
| Distances in the horizontal direction | | | | |
| Anteroposterior endoscopic distance to SPF | Between ITA and SPF (y coordinates) | 38.3 [4] | 23.8–52.5 | Length landmarks to target the cryotherapy area |
| Safety distance from auditory tube | Between SPF and most anteromedial point of the tubal orifice (xyz coordinates) | 18.2 [2.8] | 9.6–29.3 | |
| Distances in the vertical direction | | | | |
| SPF height level | Between SPF and PNS (z coordinates) | 22.6 [3.6] | 11.2–36.9 | Height landmarks to target the cryotherapy area |

Abbreviations: ITA, inferior turbinate axilla; PNS, posterior nasal spine; SPF, sphenopalatine foramen.

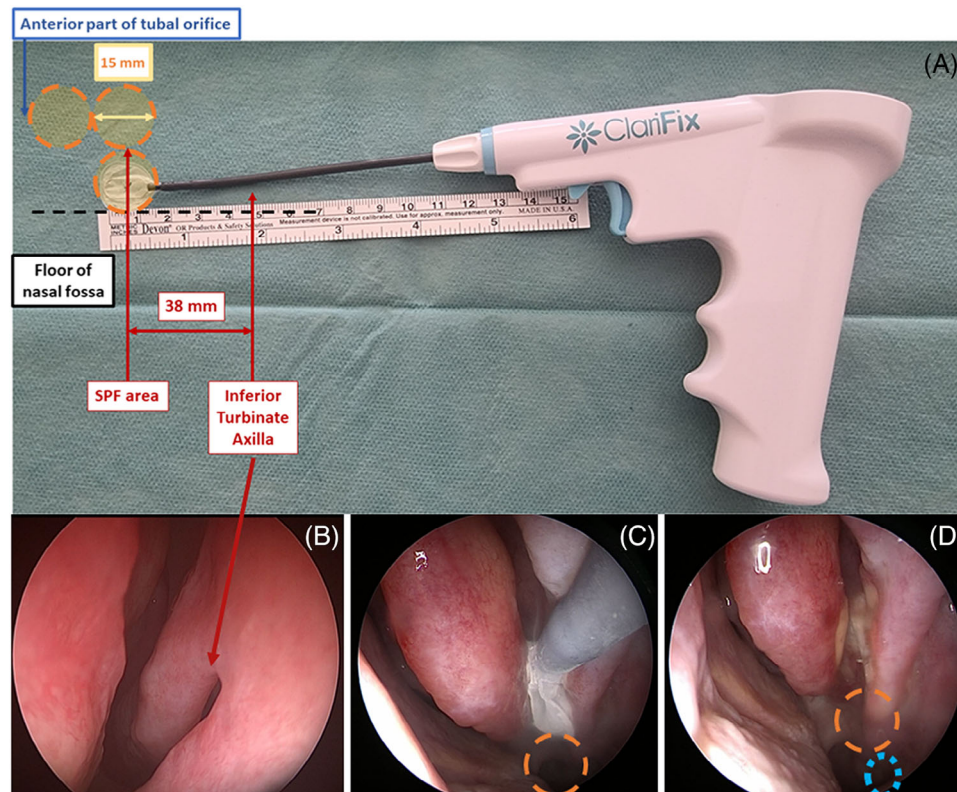


FIGURE 1 (A) Anatomical distances of interest to best target the posterior nasal nerve branches for cryotherapy. (B) Endoscopic view of the left inferior turbinate axilla. (C) Endoscopic view of cryogen application in the left SPF area, in front of the insertion of the middle turbinate. Orange circle: representation of one ClarifFix device balloon of distance from the nasal floor. (D) Endoscopic view of the same cryotherapy area after removal of the device. Orange circle: representation of one ClarifFix device balloon of distance from the tubal orifice (blue circle). SPF, sphenopalatine foramen.

should rely on direct visual and/or palpatory anatomical landmarks. CB allows freezing a circular area of at least 15 mm. In summary, to seek accurate targeting of the SPF, follow these anatomical guidelines: maintain a 38.3 mm anteroposterior distance between CB center and the ITA center, keep one CB free space (15 mm) safety margin in front of the auditory tube opening, and leave one CB free space above the nasal floor in the vertical axis. These landmarks may offer precise guidance for optimal results (Supporting Information S3).

To reduce the risk of failure, Yen et al.⁹ proposed an additional cryotherapy application in the inferior meatus near the nasal floor. According to our data, only 2.5% of patients would benefit from this second application, while exposing them to the risk of greater palatine nerve injury.

5 | CONCLUSION

This radioanatomic study sheds light on variations in the location of the SPF and offers valuable landmarks for cryogen application. However, the external validity of our findings remains limited because the population we studied had no history of CRR and further research is required to build on these findings.

CONFLICT OF INTEREST STATEMENT

Valentin Favier is a consultant for Stryker Corp.

FUNDING INFORMATION

The authors received no specific funding for this work.

ORCID

Florent Carsuzaa MD  <https://orcid.org/0000-0001-5574-8559>

Valentin Favier MD, PhD  <https://orcid.org/0000-0002-7999-951X>

REFERENCES

- Bleier BS, Schlosser RJ. Endoscopic anatomy of the postganglionic pterygopalatine innervation of the posterolateral nasal mucosa. *Int Forum Allergy Rhinol*. 2011;1(2):113-117.
- Ucerler H, Aktan Ikiz ZA, Yoruk MD, Boduc E, Ozturk L. Morphometric assessment of important landmarks on skull intended for Vidian nerve surgery. *Surg Radiol Anat*. 2020;42(9):987-993.
- Hwang PH, Lin B, Weiss R, Atkins J, Johnson J. Cryosurgical posterior nasal tissue ablation for the treatment of rhinitis. *Int Forum Allergy Rhinol*. 2017;7(10):952-956.
- Del Signore AG, Greene JB, Russell JL, Yen DM, O'Malley EM, Schlosser RJ. Cryotherapy for treatment of chronic rhinitis: 3-month outcomes of a randomized, sham-controlled trial. *Int Forum Allergy Rhinol*. 2022;12(1):51-61.
- Ow RA, O'Malley EM, Han JK, Lam KK, Yen DM. Cryosurgical ablation for treatment of rhinitis: two-year results of a prospective multicenter study. *Laryngoscope*. 2021;131(9):1952-1957.
- Fan T, Chandna M, Gorelik D, Takashima M, Yim MT, Rowan NR, et al. Correlation between middle turbinate insertion in relation to sphenopalatine foramen and failure rates of cryotherapy and radiofrequency treatment for chronic rhinitis. *Int Forum Allergy Rhinol*. 2023;13(1):88-91.
- Yushkevich PA, Piven J, Hazlett HC, Smith RG, Ho S, Gee JC, et al. User-guided 3D active contour segmentation of anatomical structures: significantly improved efficiency and reliability. *NeuroImage*. 2006;31(3):1116-1128.
- Schmale IL, Yao WC, Luong AU, Citardi MJ. The role of CT and endoscopy in the evaluation of patients referred for intranasal Cryoablation. *Am J Otolaryngol*. 2021;42(4):102971.
- Yen DM, Conley DB, O'Malley EM, Byerly TA, Johnson J. Multiple site cryoablation treatment of the posterior nasal nerve for treatment of chronic rhinitis: an observational feasibility study. *Allergy Rhinol (Providence)*. 2020;11:2152656720946996.

SUPPORTING INFORMATION

Additional supporting information can be found online in the Supporting Information section at the end of this article.

How to cite this article: Sliman J, Carsuzaa F, Tanaka L, et al. Anatomical variations of interest for posterior nasal nerve cryotherapy in the treatment of chronic rhinitis: A radioanatomic study. *Int Forum Allergy Rhinol*. 2024;14:995–998. <https://doi.org/10.1002/alr.23305>